

Pelvic Inflammatory Disease Caused by *Streptococcus Pneumoniae* in a Heavy Smoker after Laparoscopic Surgery

Dear Editor,

Pneumococcal pelvic inflammatory disease (PID) is a rare condition with only few case reports in the recent English language literature.¹⁻⁴ We report—to the best of our knowledge—the first case of pneumococcal PID from Singapore, which occurred in a heavy smoker after laparoscopic surgery.

Case Report

In February 2010, a 40-year-old Indonesian woman with a 20-pack-year history of smoking underwent laparoscopic salpingostomy for recurrent ectopic pregnancy. She was clinically well at 3 weeks follow-up. Three months post laparoscopy, she presented with persistent and worsening suprapubic pain of 2 months duration. Intravenous pyelography excluded renal calculi and pelvic ultrasound showed a large midline cystic mass measuring 14.9 cm x

11.0 cm x 6.91 cm with internal echoes, thick septations and peripheral vascularity (Figs. 1a and 1b). Clinically, the patient was afebrile with stable vital signs. Her haemoglobin was 11.6 g/dL, the white blood cell count was $16.9 \times 10^9/L$ with 81% of neutrophils and platelets were $629 \times 10^9/L$. She was commenced on IV Ceftriaxone and Metronidazole and underwent emergency diagnostic laparoscopy due to further worsening pain after admission. Intraoperatively, there was no discrete mass, instead bowel encasing the uterus and ovaries and adherent friable tissues (Fig. 1c) were noted. The surgical impression was a collection of pus beneath the severely distorted dense adhesions, which did not permit safe dissection. Therefore, only conservative surgery was performed, comprising drainage of pus through a secure window. Screening for HIV, *Treponema pallidum* antibodies and Chlamydia was negative, but culture of the pus grew pure *Streptococcus pneumoniae*. Postoperative treatment included IV Ampicillin (according to sensitivity), empiric

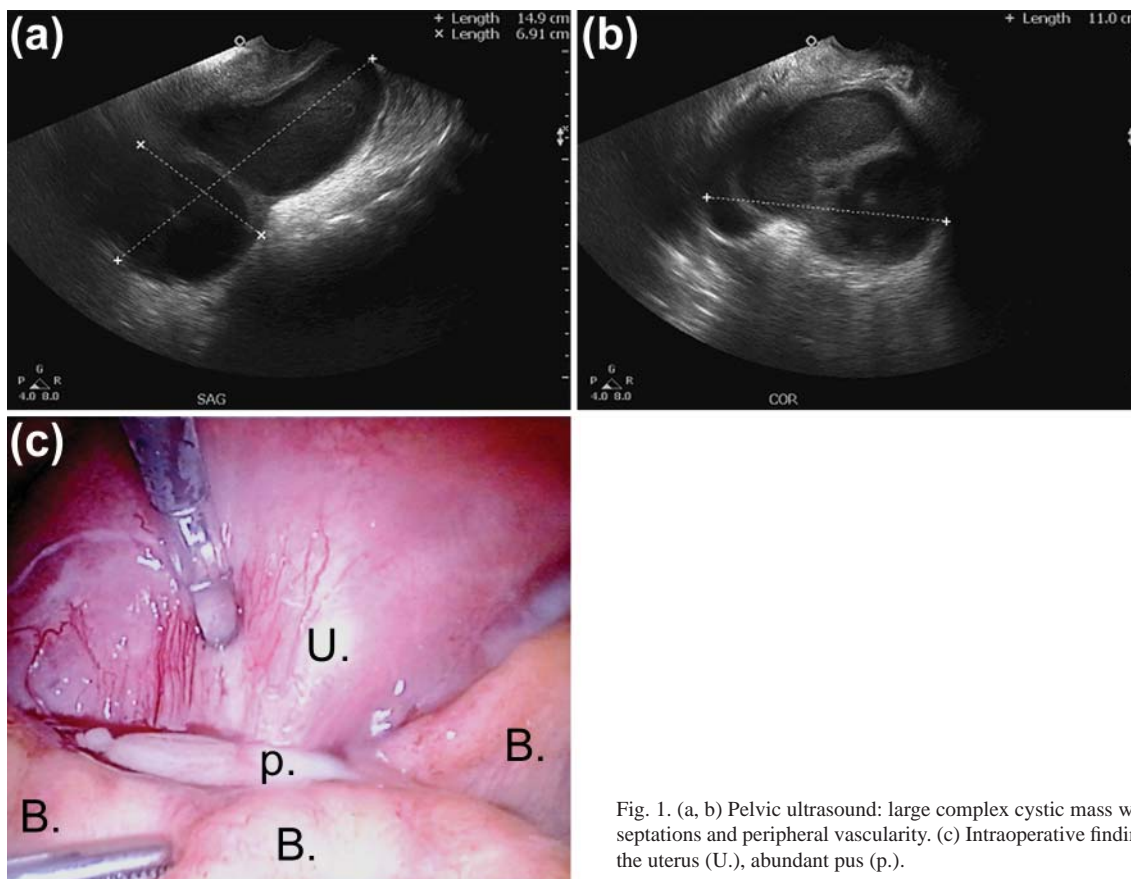


Fig. 1. (a, b) Pelvic ultrasound: large complex cystic mass with internal echoes, thick septations and peripheral vascularity. (c) Intraoperative findings: Bowel (B.) encasing the uterus (U.), abundant pus (p.).

IV Metronidazole, oral Doxycycline and smoking cessation counselling. She was discharged well after 1 week. At 6 months follow-up, she had quit smoking and her pelvic ultrasound was normal.

Discussion

A connection between invasive pneumococcal disease in adults, presenting mostly as meningitis and bacteraemia, and smoking has been established previously.⁵ Furthermore, cigarette smoking has been related to an increased risk of PID and perioperative complications.^{6,7} This case is the first report illustrating a possible link of pneumococcal PID as a particularly uncommon manifestation of invasive pneumococcal disease, smoking and preceding surgery, although a clinical scenario like this might be expected based on the indicated associations. Despite the large focus of infection and the limited drainage of pus during surgery, our patient recovered well with conservative treatment. Thus our experience confirms the overall good prognosis of pneumococcal PID with antibiotic treatment as suggested by the recent literature.¹⁻⁴ We propose that when pneumococcal PID is suspected at laparoscopy, conservative dissection and drainage is recommended to avoid injuries to surrounding structures. We postulate a causative relationship between our patient's heavy smoking and the development of pneumococcal PID after laparoscopy, due to blood spread from the lungs. Therefore we suggest that smoking cessation counselling was of significant importance in the management of this case. However, formal studies are required to confirm a higher susceptibility of smokers to PID caused by *Streptococcus pneumoniae* in the context of or independent from a surgical intervention.

REFERENCES

1. Lemoyne S, Van Leemput J, Smet D, Desmedt E, Devos H, Van Schaeren J, et al. Pelvic inflammatory disease due to *Streptococcus pneumoniae*: a usual pathogen at an unusual place. *Acta Clin Belg* 2008;63:398-401.
2. Bucher A, Muller F. Spectrum of abdominal and pelvic infections caused by pneumococci in previously healthy adult women. *Eur J Clin Microbiol Infect Dis* 2002;21:474-7.
3. Nielsen KR, Ejlersen T, El-Batran S, Prag J. A five-year survey of pneumococcal peritonitis in two Danish counties--incidence, diagnosis and clinical entities. *Clin Microbiol Infect* 2003;9:738-40.
4. Pasticci MB, Donnini A, Mencacci A, Lapalorcia LM, Cavazzoni E, Baldelli F. A diagnosis of pneumococcal peritonitis secondary to pyosalpinx in a young healthy female by culturing peritoneal pus. *New Microbiol* 2008;31:295-8.
5. Nuorti JP, Butler JC, Farley MM, Harrison LH, McGeer A, Kolczak MS, et al. Cigarette smoking and invasive pneumococcal disease. Active Bacterial Core Surveillance Team. *N Engl J Med* 2000;342:681-9.
6. Simms I, Stephenson JM. Pelvic inflammatory disease epidemiology: what do we know and what do we need to know? *Sex Transm Infect* 2000;76:80-7.
7. Turan A, Mascha EJ, Roberman D, Turner PL, You J, Kurz A, et al. Smoking and perioperative outcomes. *Anesthesiology* 2011;114:837-46.

Elisabeth Mack, ¹Dipl-human biol (Marburg, Germany), Horng Yen Wee,

¹MB BCh BAO (Dublin), MRCOG (UK), FAMS

¹Department of Obstetrics and Gynaecology, KK Women's and Children's Hospital

Address for correspondence: Dr Wee Horng Yen, Department of Obstetrics and Gynaecology, KK Women's and Children's Hospital, 100 Bukit Timah Road, Singapore 229899.
Email: mrwee@talk21.com